

# Revision of Failed Lateral Meniscal Allograft Transplant

MAJ Christopher J. Roach, MD, MAJ Brett D. Owens, MD, and COL Thomas M. DeBerardino, MD

**Abstract:** Meniscus allograft transplantation (MAT) is an acceptable procedure for the younger patient with a meniscus-deficient knee that has not yet developed advanced arthrosis. Numerous reports on good short-term clinical outcomes are present in the literature; however, reports on failures and revision MAT are relatively scarce. We report a case of a failed lateral MAT with the slotted bone technique, revised with a bone plug technique. We also review the literature for failed MAT and analyze the mode of failure in this case.

**Key Words:** meniscus allograft transplant, revision meniscus allograft transplant, meniscus allograft bone plug technique

(*Tech Knee Surg* 2009;8: 64–66)

The meniscus is important for load transmission, shock absorption, joint congruity, and stability.<sup>1</sup> Meniscectomy can lead to degenerative knee changes evidenced by increased contact pressures and increased degenerative changes.<sup>2–7</sup> Meniscal allograft transplantation has been shown to have a protective effect on the development of degenerative articular cartilage changes in experimental animal studies and can improve pain and functionality in selected patients.<sup>2,3,8</sup> Multiple techniques have been used for meniscal allograft transplantation. Although soft tissue-only fixation techniques have been reported, superior clinical results have been shown with bony fixation.<sup>8</sup> Both slotted and bone plug techniques have been described with good clinical results.<sup>9–16</sup> We report a case of failed lateral meniscal allograft performed using the slotted technique, which was successfully revised with a bone plug technique. We reviewed the literature for failed meniscal allograft transplant, analyzed the mode of failure in this case, and highlighted the advantages of the bone plug technique.

## CASE

T.D. is a 37-year-old active-duty male soldier who complains of approximately 10 years of right-knee pain. In 1995, he sustained an unclear knee injury during military training. He coped with his symptoms until undergoing a knee arthroscopy and partial lateral meniscectomy for a lateral meniscal tear in 2001. Two years later, he underwent a second arthroscopic partial lateral meniscectomy for continued symptoms. In January 2005, he underwent a third knee arthroscopy with partial lateral meniscectomy, and a meniscal allograft was ordered. In March, 2005, his size-matched fresh-frozen lateral meniscal allograft was obtained, and the patient underwent a

knee arthroscopy with a lateral meniscal allograft transplantation using a slotted technique with an interference screw.<sup>17</sup>

The patient did fairly well postoperatively; however, he continued to complain of lateral pain and was referred to us for evaluation. On examination, his limb alignment was grossly normal. His knee had no effusion and was stable on varus and valgus stress testings. The Lachman examination result was positive (grade 2B), and the posterior drawer test result was negative. The result of the McMurray testing was positive for lateral joint-line tenderness and pain. Plain radiographs were obtained to include bilateral Rosenberg and standing weight-bearing alignment views. These showed no degenerative changes in the lateral compartment and normal limb alignment. Magnetic resonance imaging (MRI) was obtained and showed heterogeneous signal changes of increasing degree for the midbody of the allograft to the anterior horn. The anterior cruciate ligament (ACL) fibers were also attenuated at their tibial insertion.

In November 2005, this patient underwent diagnostic arthroscopy where a failure of the lateral meniscal allograft was noted. The anterior horn of the allograft meniscus was detached from its bony insertion. The exposed allograft bone did not appear to have undergone any healing to the host tibia (Fig. 1). The allograft and lax ACL were debrided, and a second meniscal allograft was ordered.

In July 2006, this patient underwent a revision lateral meniscal allograft using bone plugs (Fig. 2) and a concomitant ACL reconstruction with tibialis allograft. The technique used involves the drilling of a separate tibial tunnel for both the anterior and posterior bone plugs. The allograft meniscus is placed arthroscopically, and the bone plugs are secured by tying the sutures exiting the tibial tunnels over a bony bridge.<sup>18</sup>

Rehabilitation involved toe-touch weight bearing and flexion to 90 degrees for the first 6 weeks. The patient wore a knee immobilizer during this time. He was progressed to full weight bearing and full motion by 8 weeks. Progressions of quadriceps strength and aerobic activities were followed for the next several months until return to duty.

## DISCUSSION

Preoperative evaluation and patient selection play large roles in the success of meniscal allograft transplants. Preoperative plain radiographs can evaluate lower extremity alignment and osteoarthritic changes such as joint-space narrowing, osteophyte formation, or condylar squaring. Osteophytes that interfere with anterior horn seating may also be detected radiographically. Magnetic resonance imaging may further define articular cartilage defects or advanced arthrosis. Clinical examination determines ligamentous stability and muscular weakness or atrophy. Before the original meniscal allograft transplant in this case, preoperative radiographs and MRI revealed a well-aligned lower extremity with no evidence of advanced articular cartilage injury or ligamentous injury. The examination revealed a stable knee with adequate muscular tone and strength.

Numerous meniscal allograft transplant outcome studies have reported good results of pain relief and increased function evidenced by improvements in various subjective knee scoring

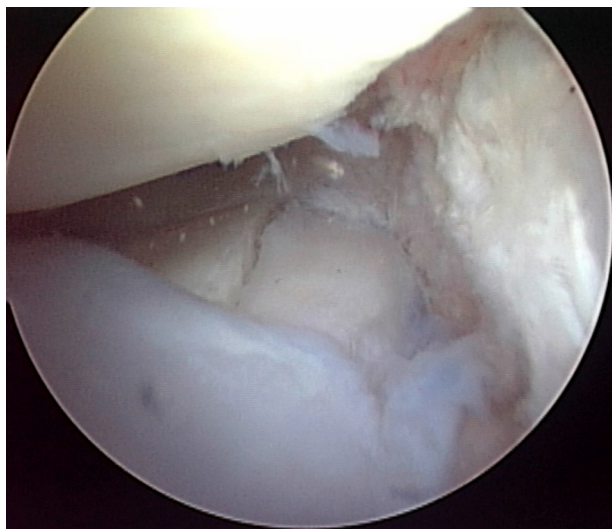
From the Orthopedic Surgery Service, Keller Army Hospital, US Military Academy, West Point, New York, New York, U.S.A.

The opinions or assertions contained herein are the private views of the authors and are not to be construed as official or reflecting the views of the Department of Defense or the United States government. The authors are employees of the US government.

No grant funding was received for this study.

Address correspondence and reprint requests to MAJ Brett D. Owens, MD, Keller Army Hospital, US Military Academy, West Point, New York, NY 10996. E-mail: b.owens@us.army.mil.

Copyright © 2009 by Lippincott Williams & Wilkins



**FIGURE 1.** Nonunion of slotted lateral meniscal allograft transplantation.

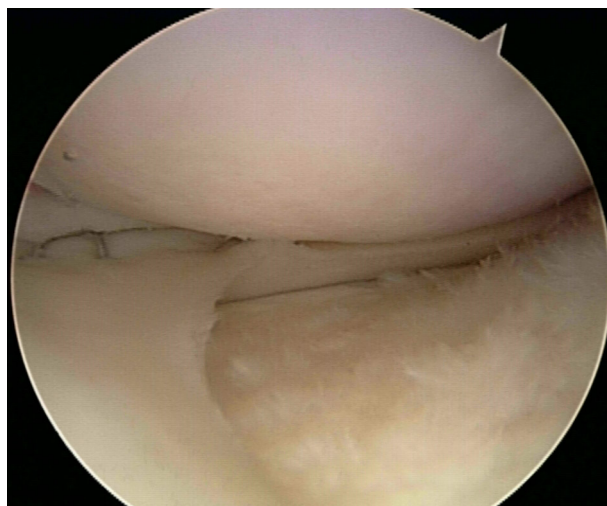
systems such as the Lysholm knee score, the Knee Injury and Osteoarthritis Outcome Score, the International Knee Documentation Committee rating, the Tegner score, the Short Form 36, and the visual analog scale.<sup>8,10,12–14,19–22</sup> In addition, many of these studies also use radiographs, MRI, and second-look arthroscopy to objectively assess osteoarthritic and meniscal changes postoperatively. Sekiya et al<sup>13</sup> reported an improved overall function and activity level of 96% for isolated lateral meniscus allograft transplantation (MAT) in 25 patients. Rath et al<sup>15</sup> evaluated 22 MATs and found an improvement in Short Form 36 scores at 2 to 8 years' follow-up in all but one patient, although 8 of the menisci had torn. The torn menisci either underwent partial meniscectomy or reimplantation of another allograft.

There are multiple differing descriptions of failure of meniscal allograft transplants in outcome studies of this procedure. Rodeo<sup>8</sup> reported 7 failures of 33 meniscal allograft transplants after objective evaluation. Although it was stated that the failures occurred in older patients (mean age, 39 years), that the failures had preoperative grade 3 or 4 articular cartilage changes, and that 3 of the 7 failures occurred in patients implanted without bone plug attachment, no clear definition of failure was given. Noyes et al<sup>16</sup> and Hommen et al<sup>20</sup> used multifactorial systems to define failure in clinical subjective scores, appearance on MRI, or those grafts that required complete or near-total meniscectomy. Survival analyses of MAT also have complicated failure definitions. Verdonk et al<sup>23</sup> reported on their first 100 MATs using specific clinical end points for failure. Failures were defined as moderate or severe occasional or persistent pain or poor knee function. Knees converted to total or unicompartmental knee arthroplasty were also considered failures. Unreasonable expectations may also lead to eventual graft failure as illustrated in the study by Sekiya et al<sup>13</sup> in which 96% of patients had overall improved function and activity levels, but only 42% could participate in moderate or strenuous sports without pain. van Arkel and de Boer<sup>24</sup> performed a survival analysis on 63 MATs and reported 13 failures. Failures were a combination of persistent pain and mechanical failure of the graft. Of note, 4 of the 5 mechanical failures occurred with rupture of the ACL. The authors found a significant negative correlation between rupture of the ACL and successful meniscal transplantation. We believe this was a

major factor in the mechanical failure of our lateral MAT in this case.

The choice of technique has had a significant impact on the outcomes of meniscal allograft transplantation. Cadaver studies have shown that bony fixation for the meniscal horns best approximates contact pressures in knees with intact menisci compared with either no horn attachment or suture attachment.<sup>4,25,26</sup> The decreased contact pressures can be achieved with a bony bridge containing bone horns or separate bony plugs. The importance of osseous fixation was manifested by Noyes and Barber-Westin<sup>27</sup> who reported a 58% failure rate for irradiated grafts implanted without bony fixation, although some of the failed grafts were implanted in patients with advanced arthrosis. Rodeo<sup>8</sup> reported clinical success in 88% of transplants performed with osseous fixation compared with the 47% performed without. Although we have had success with bony fixation, studies have also shown good short-term clinical results using suture fixation only.<sup>12,13,19,20,22</sup> In our case, the senior author chose to revise the slot technique used in the primary transplantation to the arthroscopic technique using individual bone plugs. This technique was chosen for several reasons. The main reason is that the slot technique was felt to fail in large part because of a nonunion of the allograft and the host bone. Using a slot technique for the revision would have mandated enlarging the original slot back to the fresh bone and using a larger slotted allograft on the transplanted graft, thus causing increased surgical morbidity to the involved compartment and undermining the tibial footprint of the ACL. The senior author has performed more than 120 meniscal transplants for the past decade using this technique and feels that it is easier to obtain accurate placement of the anterior and posterior bone plugs within the anatomically drilled tibial sockets. In addition, the allograft bone is the most immunogenic portion of the implanted construct. The slot technique exposes the bulk of the allograft bone to the synovial fluid that may be counterproductive to healing between the host and transplanted bone. The bone plug technique uses a minimal amount of immunogenic bone and leaves no allograft bone exposed to the synovial fluid.

Other complications that can lead to failure of a MAT are poor peripheral graft ingrowth and aggressive rehabilitation causing too much early graft displacement. de Boer and Koudstaal<sup>28</sup> reported on 3 failed MATs and concluded that



**FIGURE 2.** Revision lateral meniscal allograft transplantation using arthroscopic bone plug technique.

factors that interfere with graft vascularization, such as instability or malalignment, can lead to incomplete graft healing and early degeneration and loosening. This case illustrates the importance of knee stability for graft healing, considering that the rehabilitation protocol included limited no weight bearing for the first 6 weeks. An overly aggressive therapy regimen was not followed, but the patient did have an unstable knee due to ACL insufficiency. The instability likely had a role in the failure of the graft to heal at both the bone and soft tissue interfaces.

Meniscal allograft transplantation can provide pain relief and improve function in carefully selected patients. Preoperative evaluations of knee stability and alignment are essential in assuring the best chance for healing and long-term survival of a meniscal allograft. Bony attachment of meniscal horns have decreased intra-articular contact pressures and improved results. Mechanical failure of meniscal allografts are relatively rare in stable and well-aligned knees. Revision allograft in situations of graft failure with combined ligament reconstruction in cases of knee instability may be successful in certain cases. Further outcome studies are needed to determine the long-term effectiveness of meniscal allograft transplantation.

## REFERENCES

1. Wojtys EM, Chan DB. Meniscus structure and function. *Instr Course Lect.* 2005;54:323–330.
2. Szomor ZL, Martin TE, Bonar F, et al. The protective effects of meniscal transplantation on cartilage: an experimental study in sheep. *J Bone Joint Surg Am.* 2000;82:80–88.
3. Aagaard H, Jørgensen U, Bojsen-Møller F. Reduced degenerative articular cartilage changes after meniscal allograft transplantation in sheep. *Knee Surg Sports Traumatol Arthrosc.* 1999;7:185–191.
4. Paletta GA, Manning T, Snell E, et al. The effect of allograft meniscal replacement on intra-articular contact area and pressures in the human knee. *Am J Sports Med.* 1997;25:692–698.
5. Alhalki MM, Hull ML, Howell SM. Contact mechanics of the medial tibial plateau after implantation of a medial meniscal allograft. *Am J Sports Med.* 2000;28:370–376.
6. Dienst M, Greis P, Ellis BJ, et al. Effect of lateral meniscal allograft on contact mechanics of the lateral tibial plateau. *Am J Sports Med.* 2007;35:34–42.
7. Fairbank TJ. Knee joint changes after meniscectomy. *J Bone Joint Surg Br.* 1948;30:664–670.
8. Rodeo SA. Meniscal allografts—where do we stand? *Am J Sports Med.* 2001;29:246–261.
9. Wilcox TR, Goble EM, Doucette SA. Goble technique of meniscal transplantation. *Am J Knee Surg.* 1996;9:37–42.
10. Stollsteimer GT, Shelton WR, Dukes A, et al. Meniscal allograft transplantation: a 1- to 5-year follow-up of 22 patients. *Arthroscopy.* 2000;16:343–347.
11. Sekiya JK, Griffin RG, Irrgang JJ, et al. Clinical outcomes after combined meniscal allograft transplantation and anterior cruciate ligament reconstruction. *Am J Sports Med.* 2003;31:896–906.
12. Kim J-M, Bin S-I. Meniscal allograft transplantation after total meniscectomy of torn discoid lateral meniscus. *Arthroscopy.* 2006;22:1344–1350.
13. Sekiya JK, West RV, Groff YJ, et al. Clinical outcomes following isolated lateral meniscal allograft transplantation. *Arthroscopy.* 2006;22:771–780.
14. Cole BJ, Dennis MG, Lee SJ, et al. Prospective evaluation of allograft meniscus transplantation: a minimum 2-year follow-up. *Am J Sports Med.* 2006;34:919–927.
15. Rath E, Richmond JC, Yassir W, et al. Meniscal allograft transplantation: two- to eight-year results. *Am J Sports Med.* 2001;29:410–414.
16. Noyes FR, Barber-Westin SD, Rankin M. Meniscal transplantation in symptomatic patients less than fifty years old. *J Bone Joint Surg Am.* 2004;86:1392–1404.
17. Farr J, Meneghini RM, Cole BJ. Allograft interference screw fixation in meniscal transplantation. *Arthroscopy.* 2004;20:322–327.
18. DeBerardino TM. Arthroscopically assisted meniscal allograft transplant. *Oper Tech Sports Med.* 2006;13:227–232.
19. Verdonk PCM, Verstraete KL, Almqvist KF, et al. Meniscal allograft transplantation: long-term clinical results with radiographic and magnetic resonance imaging correlations. *Knee Surg Sports Traumatol Arthrosc.* 2006;14:694–706.
20. Hommen JP, Aplegate GR, Del Pizzo W. Meniscus allograft transplantation: ten-year results of cryopreserved allografts. *Arthroscopy.* 2007;23:388–393.
21. Ryu RKN, Dunbar WH, Morse GG. Meniscal allograft replacement: a 1-year to 6-year experience. *Arthroscopy.* 2002;18:989–994.
22. Stone KR, Walgenbach AW, Turek TJ, et al. Meniscus allograft survival in patients with moderate to severe unicompartmental arthritis: a 2- to 7-year follow-up. *Arthroscopy.* 2006;22:469–478.
23. Verdonk PCM, Demurie A, Almqvist KF, et al. Transplantation of viable meniscal allograft. survivorship analysis and clinical outcome of one hundred cases. *J Bone Joint Surg Am.* 2005;87:715–724.
24. van Arkel ERA, de Boer HH. Survival analysis of human meniscal transplantations. *J Bone Joint Surg Br.* 2002;84:227–231.
25. Alhalki MM, Howell SH, Hull ML. How three methods for fixing a medial meniscal allograft affect tibial contact mechanics. *Am J Sports Med.* 1999;27:320–328.
26. Chen MI, Branch TP, Hutton WC. Is it important to secure the horns during lateral meniscus transplantation? A cadaveric study. *Arthroscopy.* 1996;12:174–181.
27. Noyes FR, Barber-Westin SD. Irradiated meniscus allografts in the human knee: a two- to five-year follow-up. *Orthop Trans.* 1989;19:417.
28. de Boer HH, Koudstaal J. Failed meniscal transplantation: a report of three cases. *Clin Orthop.* 1994;306:155–162.