

Open Scapula Resection in Beach-Chair Position for Treatment of Snapping Scapula

Amy E. Ross, MD, Brett D. Owens, MD, and Thomas M. DeBerardino, MD

ABSTRACT

We describe a technique of resecting the superomedial border of the scapula for treatment of “snapping scapula.” We have performed 5 consecutive open resections with the patient in the beach-chair position, and results have been good. This technique may be of particular benefit in patients who undergo concomitant glenohumeral arthroscopy.

Snapping scapula was first described by Boint in 1853.¹ Also called *washboard syndrome*,² *scapulothoracic syndrome*,³ and *scapulocostal syndrome*,⁴ this condition has been attributed to multiple bony and soft-tissue abnormalities. Although variations in the bony anatomy have been described⁵ and should be considered in the evaluation of this condition, there are no consistent radiographic findings, and bony abnormalities may not be identified either clinically or

radiographically.⁶ Soft-tissue pathology includes impingement of the superomedial angle of the scapula on the periscapular bursae.⁷ When conservative management of this condition has failed, open or arthroscopic resection of bursa or bony tissue has been used to decompress and thus relieve symptoms secondary to compressive bursitis or other pathology in this region.⁶

It has been reported that open surgical resection of the superomedial angle of the scapula is effective and allows for better visualization and quantification of bone removal than does arthroscopic treatment.⁶ Although multiple open techniques have been described,^{1,8-11} none involves the beach-chair position. Our experience has been that superomedial resection of the scapula in this position not only allows for adequate visualization but may be preferred over the prone and supine positions for patients who are also undergoing concomitant shoulder procedures. Positioning in this manner obviates the need for repositioning the patient and has the advantage of avoiding

additional fluid extravasation about the shoulder.

In this article, we describe our surgical technique in 5 patients who underwent superomedial scapula resection for snapping scapula.

MATERIAL AND METHODS

Patient Selection

Between May 2005 and July 2006, the senior author (TMD) surgically treated 5 consecutive patients with chronic scapulothoracic syndrome at Keller Army Community Hospital in West Point, New York. These 5 male patients (mean age, 34 years; range, 24-41 years) had experienced periscapular pain and mechanical symptoms in 2 right and 3 left shoulders (2 dominant). Symptoms had been present for a mean of 5 years (range, 3-120 months), despite conservative management.

Surgical Technique

Each patient was placed in the standard beach-chair position (Figure 1), and the Spider positioning device (Tenet Medical Engineering, Calgary,

MAJ Ross, MD, is Orthopaedic Surgeon, Brian Allgood Army Community Hospital, Seoul, Korea.

MAJ Owens, MD, is Chief, Sports Medicine and Shoulder Surgery, William Beaumont Army Medical Center, El Paso, Texas.

COL DeBerardino, MD, is Director, John A. Feagin, Jr., Sports Medicine Fellowship, Department of Orthopaedic Surgery, Keller Army Community Hospital, West Point, New York.

Address correspondence to: Amy E. Ross, MD, 121 CSH, Unit 15422, Box 338, APO, AP 96205-5244 (tel, 011-822-7917-5530/5531; fax, 011-822-7917-6322; e-mail, amy.ross@amedd.army.mil, amyrossmd@gmail.com).

Am J Orthop. 2009;38(5):249-251. Copyright 2009, Quadrant HealthCom Inc. All rights reserved.

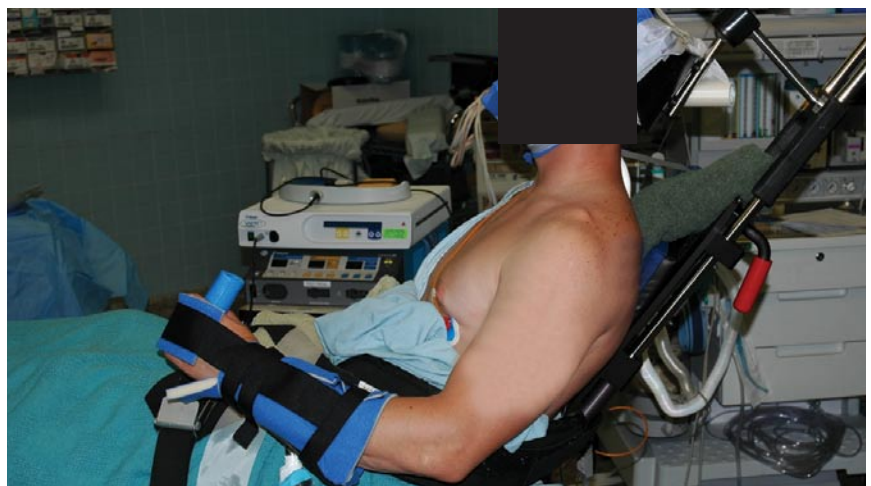

Figure 1. Each patient was placed in the standard beach-chair position.

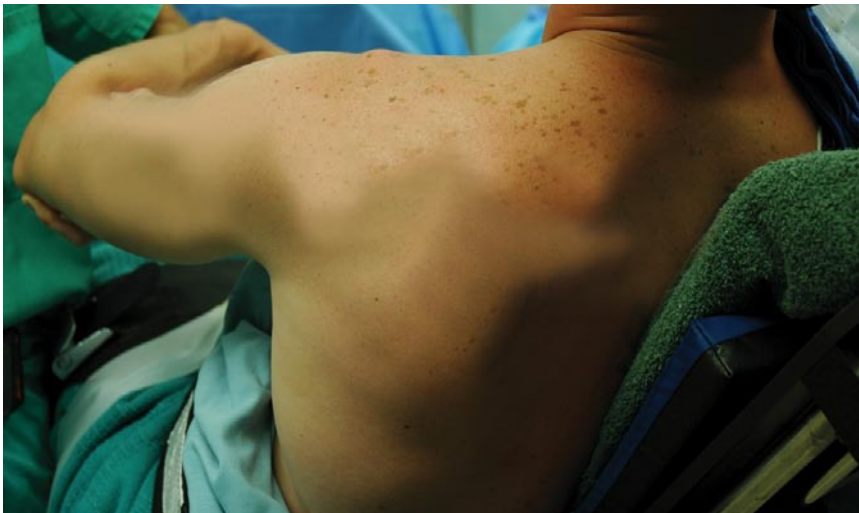

Figure 2. Spider positioning device (Tenet Medical Engineering, Calgary, Canada) was used to assist in protracting the scapula.

Canada) was used to assist with protraction of the scapula (Figure 2). (An assistant can also perform this function.) After glenohumeral and subacromial arthroscopy, as indicated, a 5-cm oblique incision was made over the superomedial border of the scapula from the superolateral to the inferomedial aspect and ending at the medial border of the scapula spine (Figure 3). Dissection was performed down to the bony scapular spine. The superomedial border of the scapula was dissected subperiosteally using blunt Cobb elevators to lift the supraspinatus muscle belly off the fossa. An electrocautery device was used to subperiosteally dissect the levator scapula and rhomboid minor off the superior and medial borders, respectively. In this way, the anterior and posterior superior medial muscles were maintained to their periosteal attachments. A microsagittal saw was used to make an oblique resection of bone at a 45° angle from the junction of the spine and medial border of the scapula, and care was taken to stay a finger breadth medial to the suprascapular notch (Figure 4). After meticulous hemostasis was maintained and irrigation performed, a running absorbable suture was used to close the fascia of the supraspinatus to the fascia of the infraspinatus over the scapular spine. The wound was then closed in the standard fashion.

Postoperative Treatment

After surgery, patients were placed in a shoulder immobilizer in slight abduction and neutral rotation to prevent periscapular muscle contraction. They were maintained in this brace, with removal for Codman exercises several times a day, for 2 weeks. Then passive and active assisted range of motion was initiated. Gentle strengthening was started at week 8 and continued until 12 weeks after surgery, when resistive exercises began. Patients usually return to sports 4 to 6 months after surgery, when proper thoracic posture, scapular control, and strength are obtained.¹²

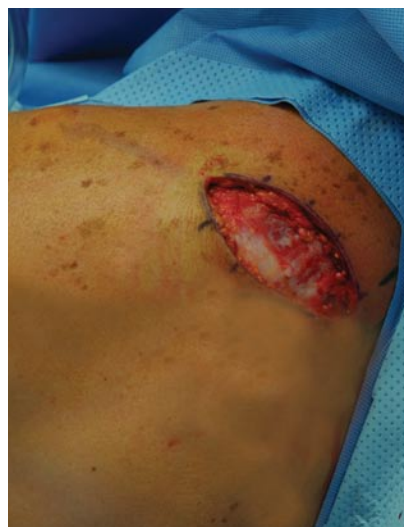

Figure 3. Oblique incision from superolateral to inferomedial aspect over superomedial border of scapula and ending at medial border of scapula spine.

RESULTS

Three of these patients underwent glenohumeral arthroscopy immediately before their open scapula resection. One patient had a posterior labral tear, which was repaired with suture anchors. Another patient had paralabral cyst decompression in conjunction with superior labrum antero-posterior and Bankart repairs, and a subacromial bursectomy before the open surgical procedure. The third patient had no significant intra-articular pathology. Two patients did not undergo subacromial or glenohumeral arthroscopy. Mean surgical time for these 2 patients without additional arthroscopy was 44 minutes.

One of the 5 patients was noted to have an inflamed supraserratus bursa during the procedure. Three patients had abnormal bony prominences. All patients were taken through a range of motion after surgery. There was no residual crepitus of the scapula on the thorax.

Mean follow-up was 12 months (range, 2-27 months). No patient had neurovascular or wound complications. All 5 patients had resolution of preoperative mechanical symptoms and returned to full active-duty status. In addition, they each had documented full range of motion and normal strength. One patient who initially had complete pain relief developed

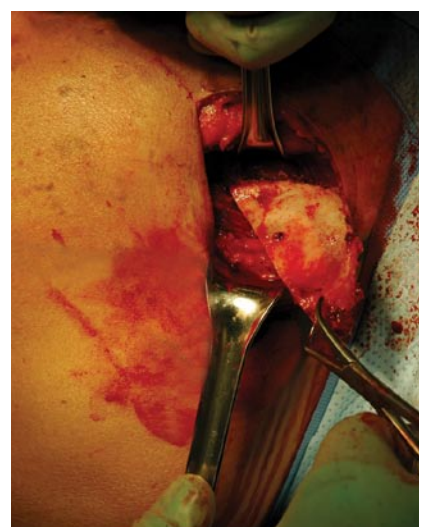


Figure 4. Oblique resection of bone at 45° angle from junction of spine and medial border of scapula.

surgical site pain 15 months later, after prolonged ruck-sack marches during deployment.

DISCUSSION

Both open and arthroscopic techniques have been used to address bone and bursal pathology in the treatment of snapping scapula.¹³ Potential advantages of arthroscopy include improved cosmesis and earlier rehabilitation.¹³ However, portal placement requires deep penetration of the rhomboids,

Potential advantages of performing superomedial scapula resection in an open fashion using the beach-chair position include minimizing operative time by prepping and draping the patient only once and using the same position to address both glenohumeral and scapulothoracic pathology. In addition, fluid extravasation to the ipsilateral shoulder is minimized by performing this procedure in an open fashion. Decreasing fluid extravasation becomes even more important

The opinions or assertions contained herein are the private views of the authors and are not to be construed as official or as reflecting the views of the US Department of the Army or the US Department of Defense.

REFERENCES

1. Richards RR, McKee MD. Treatment of painful scapulothoracic crepitus by resection of the superomedial angle of the scapula: a report of three cases. *Clin Orthop*. 1989;(247):111-116.
2. Cohen JA. Multiple congenital anomalies: the association of seven defects including multiple exostoses, von Willebrand's disease, and

“Potential advantages of performing superomedial scapula resection in an open fashion using the beach-chair position include minimizing operative time...and using the same position to address both glenohumeral and scapulothoracic pathology.”

and avoidance of surrounding neurovascular structures makes visualization and access to the superomedial border of the scapula technically challenging.^{12,14} In addition, care must be taken to avoid penetrating the thoracic cavity when establishing the medial portals.¹⁴ Complications of scapulothoracic arthroscopy include intraoperative swelling necessitating cessation of the procedure¹³ and inability to evaluate the potentially painful trapezoid bursa.¹²

Traditionally, the prone position has been used for arthroscopic scapula bone and bursal resection. In this “chicken-wing position,” the patient’s shoulder is extended with the arm in internal rotation and the dorsum of the hand on the back.¹³ Chan and colleagues¹⁴ described a modification of this approach—using the lateral position so that concurrent glenohumeral arthroscopy may be performed.

when glenohumeral arthroscopy is performed concomitantly. The incision is small, operative time is minimized, and visualization is excellent. The Spider positioning device protracts the scapula and holds a stable position when the actual bony resection is performed. No complications have arisen in our patient population using this technique.

CONCLUSIONS

Open resection of the superomedial scapula using the beach-chair position is both technically possible and advantageous, especially when performing concurrent glenohumeral arthroscopy.

AUTHORS’ DISCLOSURE STATEMENT AND ACKNOWLEDGMENTS

The authors report no actual or potential conflict of interest in relation to this article.

3. Moseley HF. *Shoulder Lesions*. 2nd ed. New York, NY: Hoeber; 1933.
4. Shull JR. Scapulocostal syndrome: clinical aspects. *South Med J*. 1969;62(8):956-959.
5. Edelson JG. Variations in the anatomy of the scapula with reference to the snapping scapula. *Clin Orthop*. 1996;(322):111-115.
6. Lehtinen JT, Macy JC, Cassinelli E, Warner JJ. The painful scapulothoracic articulation: surgical management. *Clin Orthop*. 2004;(423):99-105.
7. DeLee JC, Drez D, Miller MD. *Orthopaedic Sports Medicine*. 2nd ed. Philadelphia, PA: Elsevier; 2003.
8. Manske RC, Reiman MP, Stovak ML. Nonoperative and operative management of snapping scapula. *Am J Sports Med*. 2004;32(6):1554-1565.
9. Milch H. Partial scapulectomy for snapping of the scapula. *J Bone Joint Surg Am*. 1950;32(3):561-566.
10. Strizak AM, Cowen MH. The snapping scapula syndrome: a case report. *J Bone Joint Surg Am*. 1982;64(6):941-942.
11. Wood VE, Verska JM. The snapping scapula in association with the thoracic outlet syndrome. *Arch Surg*. 1989;124(11):1335-1337.
12. Milch H. Snapping scapula. *Clin Orthop*. 1961;20:139-150.
13. Harper GD, McIlroy S, Bayley JI, Calvert PT. Arthroscopic partial resection of the scapula for snapping scapula: a new technique. *J Shoulder Elbow Surg*. 1999;8(1):53-57.
14. Chan BK, Chakrabarti AJ, Bell SN. An alternative portal for scapulothoracic arthroscopy. *J Shoulder Elbow Surg*. 2002;11(3):235-238.