

# Insertional Footprint Anatomy of the Pectoralis Major Tendon

PAUL CAREY; BRETT D. OWENS, MD

## abstract

Full article available online at [OrthoSuperSite.com/view.asp?rID=00000](http://OrthoSuperSite.com/view.asp?rID=00000)

Correct anatomical repair of pectoralis major tendon injuries requires accurate identification of the humeral insertion site. In the absence of residual fibers at the insertion, proper placement requires knowledge of the anatomic relationships in the proximal humerus. This anatomic study attempts to measure these relationships, and the dimensions of the insertional footprint to assist in surgical repair and reconstruction. Six matched pairs of cadaver proximal humeri were examined. All specimens were found to be in good condition and none were excluded. The proximal to distal length and maximum width of the pectoralis major tendon were measured at the humeral insertion with a digital caliper. The distance from the superomedial corner of the greater tuberosity to the superior aspect of the tendon insertion was also measured. The mean proximal to distal dimension of the pectoralis major insertion was  $72.3 \pm 12.3$  mm. The mean maximal thickness at the humeral insertion was  $1.4 \pm .2$  mm. The distance from the superomedial corner of the greater tuberosity to the bony tendon insertion was  $42.2 \pm 8.5$  mm. The anatomic location of the humeral insertion of the pectoralis major tendon can be located in repair of pectoralis tendon injuries by referencing the superomedial corner of the greater tuberosity and the lateral lip of the bicipital groove. Findings in the present study will improve knowledge of the surgical anatomy relevant to repair and reconstruction of the pectoralis major tendon.

*Dr Carey is from William Beaumont Army Medical Center, El Paso, Texas; and Dr Owens is from the Department of Orthopedic Surgery, Keller Army Hospital, West Point, New York.*

*Financial Disclosure:*

*Correspondence should be addressed to: Brett D. Owens, MD, Keller Army Hospital, Department of Orthopedic Surgery, 900 Washington Rd, West Point, NY 10996 (b.owens@us.army.mil).*

*doi: 10.3928/01477447-20091124-27*

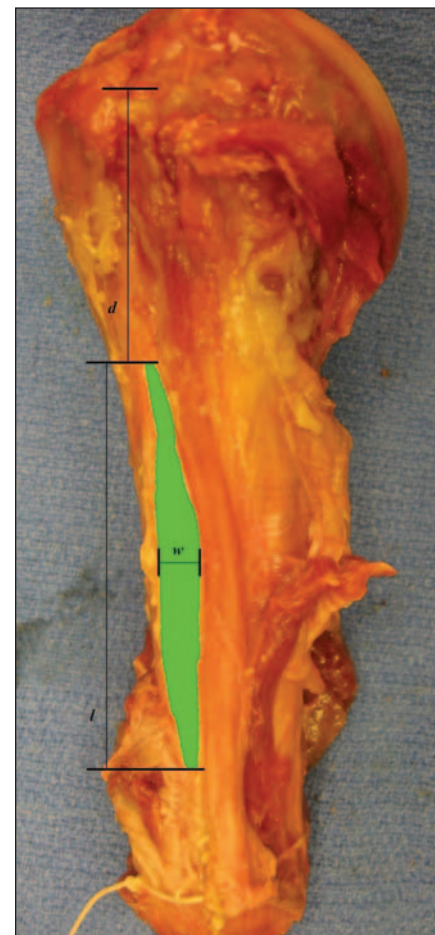


Figure: Need caption. Need caption. Need caption. Need caption. Need caption.

Rupture of the pectoralis major muscle is a rare injury, with approximately 150 cases reported in the literature since it was originally described by Patissier in 1822.<sup>1</sup> Most commonly it occurs in young active patients, frequently weight lifters during the bench press. Acute complete rupture of the pectoralis major tendon is an indication for surgical repair. Primary repair of these injuries has

typically been done with suture anchors or bone tunnels. However, placement of the ruptured tendon in its anatomical position can be difficult particularly when residual fibers of the humeral insertion are not present or are obscured. Particularly challenging are chronic rupture cases, which may require allograft reconstruction.

Although radiographic landmarks have been noted previously, we are unaware of any study involving landmarks that can be used intraoperatively to achieve anatomic repair. This article presents an examination of the humeral footprint of the pectoralis tendon insertion to assist in anatomical repair of pectoralis ruptures.

### MATERIALS AND METHODS

An anatomical study was performed on 6 matched pairs of proximal humeri after approval was obtained from the Institutional Review Board. All humeri were dissected and the humeral attachment of the pectoralis tendon was identified. Exclusion criteria included evidence of prior surgery or trauma to the tendon insertion. All specimens were found to be in adequate condition and none were excluded.

The dimensions of the footprint as well as the distances to key anatomical landmarks of the proximal humerus were measured with digital calipers. The insertion site was measured from the proximal edge to the distal edge. The thickest part of the tendon insertion was measured. No attempt was made to differentially measure the anterior and posterior layers of the insertion. Finally, the distance between the superomedial corner of the greater tuber-

osity and the superior margin of the insertion was measured (Figure).

For the purpose of statistical analysis, each matched pair was considered an independent specimen. A descriptive analysis was performed to include mean, range, and standard deviation.

### RESULTS

Six matched pairs of shoulders were dissected for measurement and none were excluded. The mean proximal to distal length of the pectoralis tendon was  $72.3 \pm 12.3$  mm. The mean maximal thickness of the tendon at the insertion was  $1.4 \pm 0.2$  mm. The mean distance from the greater tuberosity articular margin to the superior aspect of the tendon insertion was  $42.2 \pm 8.5$  mm (Table).

Where they were separable, all specimens were found to consist of no more than 2 discrete layers at the insertion. The anterior layer coursed superiorly in the medial direction while the posterior layer coursed inferiorly.

### DISCUSSION

Pectoralis major tendon tears are relatively uncommon, however, they occur in young active individuals who lift weights, such as athletes and military personnel.<sup>2</sup> One of the challenges of surgical repair is repairing the retracted tendon to its anatomic location. Insertional avulsions leave little remnant tendon tissue with which to identify the insertional footprint. Chronic rupture cases also present a surgical challenge to locating the site for anatomic repair and may even require allograft tendon reconstruction. To our knowledge, the insertional anatomy of the pectoralis major tendon has not been described. We are also unaware of the description of any anatomic landmarks to help guide repair.

This study is a descriptive cadaveric evaluation of the pectoralis major tendon insertion. We found that dimensions of the tendon at its insertion were roughly 72 mm in length and 1.4 mm in width. The superiormost extent of this insertion was

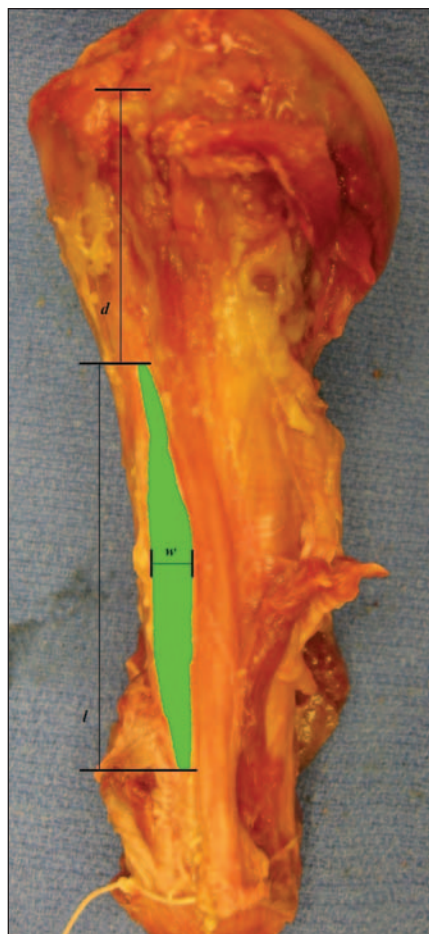


Figure: Need caption. Need caption. Need caption. Need caption. Need caption.

TABLE				
Descriptive Measures of Pectoralis Major Insertion <sup>a</sup>				
Variable	N	Mean±SD	Minimum	Maximum
Distance to GT (d)	6	42.2±8.5	30.8	49.7
Thickness (w)	6	1.4±0.2	1.0	1.6
Length proximal-distal (l)	6	72.3±12.3	50.8	87.4

<sup>a</sup>All measurements in mm.

roughly 42 mm inferior to the superomedial corner of the greater tuberosity. This landmark can be used to help guide repair of the ruptured tendon to its anatomic insertional location.

One prior study of the pectoralis footprint dimensions was identified. This study reported the proximal to distal lengths of the anterior and posterior layers separately as 66 and 77 mm respectively. The posterior layer was found to extend 11 mm more proximal than the anterior layer. This length assessment correlates well with our data. The same study found the thickness of the 2 layers at the insertion to be 2 mm each.<sup>3</sup> We were unable to differentiate the layers as this study described, and our thickness measurement was less at 1.4 mm on average.

Whether the pectoralis tendon “twists” has been debated in the literature, the tendon has been reported to rotate on itself so that the fibers of the most inferior part of the sternal head insert superiorly and the more superior fibers insert inferiorly, thus accounting for the rounded appearance of the anterior axillary fold.<sup>4</sup> Other studies have noted a similar twisting morphology.<sup>5,6</sup> However, a recent dissection and comprehensive digital reconstruction study stated, “The most inferior SH segment in all specimens was found to fold anteriorly forming a trough that cradled the inferior aspect of the adjacent superior segment. No twisting of either the PM muscle or tendon was noted.”<sup>3</sup> As a result, the inferior most segments of the sternal head are maximally stretched when the arm is abducted, externally rotated and extended causing them to fail first in activities such as the bench press.<sup>1</sup> The inferior 2 to 3 segments are relatively smaller

than the superior segments and the anterior axillary fold may persist when they are only partially torn, complicating the clinical diagnosis.<sup>3</sup>

The pectoralis tendon inserts as a thin band directly lateral to the lateral lip of the bicipital groove on the proximal humerus. Most prior studies of pectoral tendon morphology have found that at the insertion, the tendon is comprised of two layers; the clavicular head which forms the anterior insertion and the sternocostal head which forms the posterior insertion.<sup>3,5,7</sup> The anterior layer of the tendon is longer than the posterior layer and the 2 are continuous inferiorly.<sup>3</sup> One study identified a third middle layer.<sup>7</sup> Our descriptive cadaveric study confirmed the presence of only 2 discrete layers.

Defining the insertional anatomy is important since most cases of pectoralis major tendon rupture occur at the insertion. In 86 surgically verified cases reported by Bak et al, the most common sites of rupture were at the insertion (n=56) and at the myotendinous junction (n=21) followed by bony avulsion (n=4), tendon substance (n=3), and muscle belly (n=2). Ruptures at the tendon insertion occur more commonly at low speed (ie, weight lifting) while ruptures at the myotendinous junction occur at high speed (ie, falls, water skiing, high speed trauma).<sup>8</sup>

Limitations of our study include a small sample size with 6 matched pairs. The use of additional cadaveric specimens could minimize the variability seen in our insertion dimensional measurements. The strengths of our study are the use of a clinically relevant anatomic landmark that can be used to reliably locate the pectoralis major tendon insertion.

## CONCLUSION

The pectoralis tendon is a wide, thin tendon (72×1.4 mm) that inserts just lateral to the bicipital groove. The vertical location along this groove can be determined by referencing the superomedial corner of the greater tuberosity (42 mm above superior aspect of tendon insertion). These landmarks can be used to help guide repair and reconstruction of pectoralis tendon rupture. ■

## REFERENCES

1. Kakwani RG, Matthews JJ, Kumar KM, Pimpalnerkar A, Mohtadi N. Rupture of the pectoralis major muscle: surgical treatment in athletes (published ahead of print July 18, 2006). *Int Orthop*. 2007; 31(2):159-163.
2. White DW, Wenke JC, Mosely DS, Mountcastle SB, Basamania CJ. Incidence of major tendon ruptures and anterior cruciate ligament tears in US Army soldiers (published online ahead of print April 27, 2007). *Am J Sports Med*. 2007; 35(8):1308-1314.
3. Fung L, Wong B, Ravichandiran K, Agur A, Rindlisbacher T, Elmaraghy A. Three-dimensional study of pectoralis major muscle and tendon architecture. *Clin Anat*. 2009; 22(4):500-508.
4. Petilon J, Carr DR, Sekiya JK, Unger DV. Pectoralis major muscle injuries: evaluation and management. *J Am Acad Orthop Surg*. 2005; 13(1):59-68.
5. Ashley GT. The manner of insertion of the pectoralis major muscle in man. *Anat Rec*. 1952; 113(3):301-307.
6. Lee J, Brookenthal KR, Ramsey ML, Kneeland JB, Herzog R. MR imaging assessment of the pectoralis major myotendinous unit: an MR imaging-anatomic correlative study with surgical correlation. *AJR Am J Roentgenol*. 2000; 174(5):1371-1375.
7. Wolfe SW, Wickiewicz TL, Cavanaugh JT. Ruptures of the pectoralis major muscle. An anatomic and clinical analysis. *Am J Sports Med*. 1992; 20(5):587-593.
8. Bak K, Cameron EA, Henderson JJ. Rupture of the pectoralis major: a meta-analysis of 112 cases. *Knee Surg Sports Traumatol Arthrosc*. 2000; 8(2):113-119.